

# Neuromuscular Ultrasound Evaluation and Diagnosis of Suprascapular Nerve Entrapment Syndrome in Parsonage-Turner Syndrome

Ankur A. Patel, DO<sup>†</sup>; Xiaoning (Jenny) Yuan, MD, PhD<sup>‡</sup>; Christopher J. Visco, MD<sup>†</sup>

<sup>†</sup>Department of Rehabilitation and Regenerative Medicine, NewYork-Presbyterian Hospital/Columbia University Irving Medical Center, New York, NY

<sup>‡</sup>Department of Physical Medicine and Rehabilitation, Uniformed Services University of the Health Sciences, Bethesda, MD

## INTRODUCTION

Parsonage-Turner Syndrome (PTS), also known as neuralgic amyotrophy, is a rare disorder often presenting with unilateral shoulder pain, followed by progressive neurologic deficits of motor weakness and dysesthesias<sup>1</sup>.

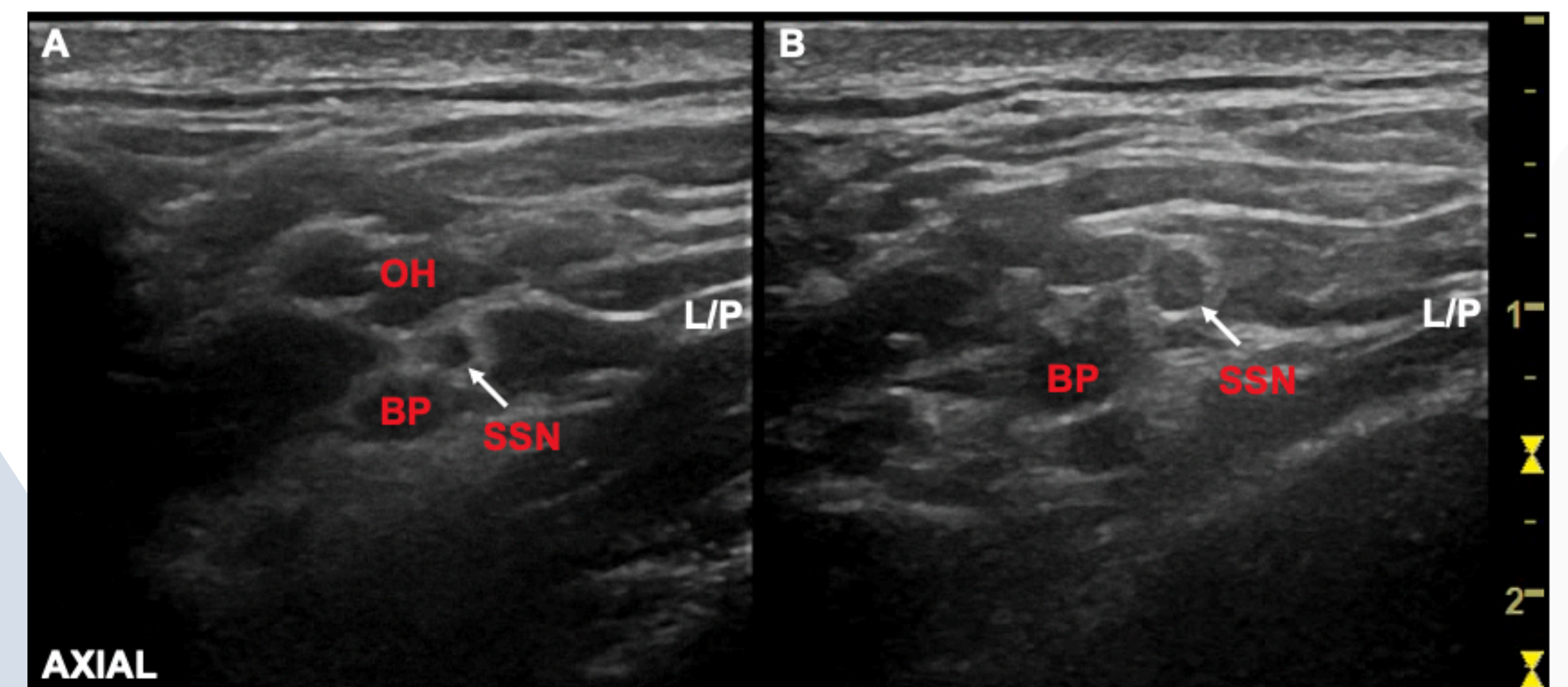
Symptoms present typically after a localized infection, specifically viral, or immunological process. In majority of cases, the suprascapular nerve (SSN) is affected and leads to pathological nerve and/or fascicle swelling that can result in focal compression at various anatomical sites<sup>2</sup>.

## PRESENTATION

A 46-year-old male with no significant history was diagnosed with PTS, affecting the left suprascapular and axillary nerves. Patient initially presented with acute onset of severe neck pain and left shoulder numbness, after a game of volleyball.

- Physical Examination: Atrophy of the left supraspinatus, infraspinatus, and deltoid muscles, with weakness in forward flexion, abduction, and external rotation. Strength, reflexes, and sensation were otherwise intact.
- MRI of cervical spine: mild narrowing of the spinal canal, left lateral recess, and left neural foramen at C5-6.
- MRI of the left shoulder demonstrated mild infraspinatus and supraspinatus tendinosis without tear, and tears of the anterior and posterior inferior labrum with a tiny paralabral cyst.
- MRI of the left brachial plexus - intramuscular edema within the left infraspinatus, supraspinatus, and deltoid muscles.
- Electrodiagnostic (EDX) testing - denervation, primarily in the left deltoid.
- Diagnostic ultrasound - diffuse enlargement of the axillary nerve at the level of and distal to the quadrilateral space, and diffuse enlargement of the suprascapular nerve (SSN) at the suprascapular notch, measuring 10 mm<sup>2</sup> in cross-sectional area. Focal compression of the SSN by 50% beneath the omohyoid muscle (Figure 1).

## IMAGING



**Figure 1.** Diagnostic Ultrasound of the left neck in axial view. A. Suprascapular nerve (SSN) is seen branching off the upper trunk of the brachial plexus (BP) and is compressed as it travels beneath the omohyoid (OH) muscle, as seen by the decreased cross-sectional area of the SSN. B. As the SSN travels distally and passes the OH muscle, the cross-sectional area of the SSN increases. L/P, lateral/posterior.

## DISCUSSION

- The SSN arises from the upper trunk of the brachial plexus, continues along the posterior triangle of the neck, parallel to the inferior belly of the omohyoid muscle before it courses through the suprascapular notch.
- SSN entrapment is frequently seen at the suprascapular and spinoglenoid notch; however, diffuse enlargement of the nerve in PTS can cause unique focal entrapments such as below the omohyoid muscle.

## CONCLUSION

Neuromuscular ultrasound is a vital tool in the diagnosis of superimposed entrapment neuropathies, in conjunction with standard-of-care EDX and MRI, and should be incorporated early in evaluation and management.

## REFERENCES

1. Feinberg JH, Radecki J. Parsonage-turner syndrome. *HSS J.* 2010;6(2):199-205. doi:10.1007/s11420-010-9176-x
2. Gaskin CM, Helms CA. Parsonage-Turner syndrome: MR imaging findings and clinical information of 27 patients. *Radiology.* 2006;240(2):501-507. doi:10.1148/radiol.2402050405

