Mini Case Series: Dysphagia and complications of dermatomyositis during inpatient rehabilitation

Ryan T. Sankovic, MD, Amanda Reyes, MD, Jared McCallum, MD, Melissa Mafiah, MD, P. Tyler Roskos, PhD

Beaumont Taylor Physical Medicine and Rehabilitation

Beaumont

INTRODUCTION

Dermatomyositis is a rare systemic autoimmune inflammatory disease which classically presents with proximal muscle weakness and a violet or dusty red colored rash involving the face, arms, legs and trunk. Incidence is estimated to be about 9.63 per 1,000,000 people.[1] There is a strong correlation of underlying malignancy with studies varying from 3% to 40% with 59% being asymptomatic at time of diagnosis.[2-3] The inflammatory myositis poses multiple rehabilitation challenges. Dysphagia is a common complication of all inflammatory myositis with approximately an 7.9% incidence.[4] Percutaneous endoscopic gastrostomy (PEG) tubes are often required and have a high 1-year mortality at 31%.[4] Most common cause of death in dermatomyositis patients is respiratory failure from aspiration pneumonia.[4]

CASE REPORT 1

Case 1 is a 59-year-old male with past medical history of diabetes mellitus. The patient had been suffering for several months from generalized body aches, rash in face and trunk, and proximal muscle weakness. During medical evaluation he was found to have elevated creatinine phosphokinase (CPK), positive ANA, C-Reactive Protein and anti-smooth muscle cell antibody. An MRI of the shoulder showed muscle edema, consistent with inflammatory myositis. He underwent left shoulder biopsy that was positive for necrotizing myopathy. He was treated with a high dose steroid regimen and methotrexate. His hospital course was complicated by dysphagia with a failed modified barium swallow test (MBS). PEG tube was placed. He was transferred to inpatient rehabilitation (IPR). His rehabilitation course was complicated transaminitis secondary to methotrexate use. His dysphagia did not improve. He was discharged home after 17 days with a Functional Independence Measurement (FIM) of 75. Four months post-IPR the patient lost 60lbs and was diagnosed with stage IVB epiglottis squamous cell carcinoma. Patient passed away about 13 months following IPR.

CASE REPORT 2

Case 2 is a 69-year-old male with past medical history of eczema, hypertension, prostate cancer and previous stroke. Patient initially presented with proximal muscle weakness, skin rash and dysphagia. Workup showed elevated CPK and a positive ANA. Myositis specific antibodies were negative; but muscle biopsy was consistent with myositis which confirmed the diagnosis of dermatomyositis. He was treated with high dose steroids, a single dose of intravenous gammaglobulin and long term mycophenolic acid. The patient failed a MBS and required PEG tube placement for dysphagia. Patient was transferred to IPR. His swallowing did not improve despite continued speech therapy during IPR. He was admitted to IPR for 18 days and was discharged home with home care having a discharge FIM score of 88. His dysphagia remained present outpatient during close rheumatology follow up. He presented to the acute care hospital 11 months following IPR with 27lb weight loss and was diagnosed with metastatic cancer involving his lungs, brain, liver, bilateral adrenal glands, and esophagus. Primary cancer source was determined to be small cell lung cancer after biopsy. He was discharged home with hospice and passed away less than 1 month later.

RADIOLOGY IMAGES

Case 1

Figure 1: Primary squamous cell carcinoma on PET CT

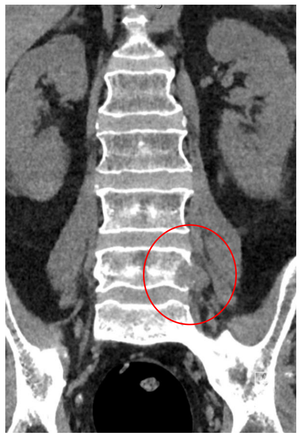

Figure 2: Left L5 neuroforaminal metastatic disease

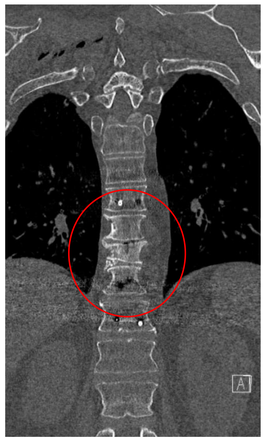

Figure 3: T10 pathologic compression fracture with 20% height loss

Case 2

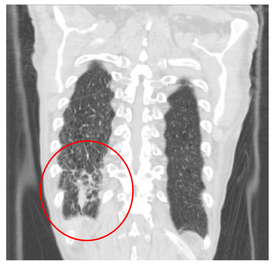

Figure 4: Primary small cell carcinoma on CT

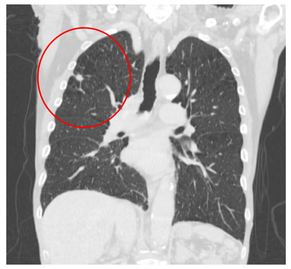

Figure 5: Right upper lung metastasis

Figure 6: Multiple liver metastases

Figure 7: Brain metastasis

DISCUSSION

Dysphagia greatly impacts patients' nutrition status, healthcare costs and quality of life. There should be a high suspicion of underlying cancer in dermatomyositis patients with incidence of 3-40%.[2] Patient's with dermatomyositis require a specialized rehabilitation plan to promote gains in strength and aerobic endurance while avoiding isolated eccentric muscle contractions. Evidence supports screening for underlying malignancy which is estimated to be prevalence in less than 10% (6.8%) of patients at time of diagnosis.[3 4] Dysphagia in dermatomyositis is often refractory to swallowing exercises and compensatory swallowing strategies. In therapy sometric and range of motion exercises are recommended as strengthening is deferred until inflammation is controlled.[5]

CONCLUSION

Nutrition is critically important in dermatomyositis patients as protein is needed to regain muscle. Close monitoring of weight and renal function should be regularly performed. PEG site care and dysphagia can be addressed in IPR. Patients receiving adequate nutrition who continue to lose weight should be investigated for underlying malignancy. For best outcomes patient's require clear communication between an interdisciplinary team.

REFERENCES

1. Bendewald, Margo J et al. "Incidence of dermatomyositis and clinically amyopathic dermatomyositis: a population-based study in Olmsted County, Minnesota." *Archives of dermatology* vol. 146,1 (2010): 26-30. doi:10.1001/archdermatol.2009.328
2. Lu, Xin et al. "Factors predicting malignancy in patients with polymyositis and dermatomyostis: a systematic review and meta-analysis." *PloS one* vol. 9,4 e94128. 8 Apr. 2014, doi:10.1371/journal.pone.0094128
3. Leatham, Hayley et al. "Evidence supports blind screening for internal malignancy in dermatomyositis: Data from 2 large US dermatology cohorts." *Medicine* vol. 97,2 (2018): e9639. doi:10.1097/MD.0000000000009639
4. Oh, Terry H et al. "Dysphagia in inflammatory myopathy: clinical characteristics, treatment strategies, and outcome in 62 patients." *Mayo Clinic proceedings* vol. 82,4 (2007): 441-7. doi:10.4065/82.4.441
5. Cuccurullo, Sara J., et al. *Physical Medicine and Rehabilitation Board Review*. Demos Medical, an Imprint of Springer Publishing, 2020.