

Conversion of Stuporous Catatonia to Excited Catatonia from Lorazepam Challenge

James Price, MD, Davis Gerew, Ruqiyah Shama Tareen, MD
Western Michigan University Homer Stryker M.D. School of Medicine
Department of Psychiatry, Kalamazoo, MI

Background

Catatonia, a motor dysregulation syndrome with behavioral components, has gone through many conceptual changes since its inception as a syndrome by Kahlbaum in 1874.^{1,2} The concept of catatonia as a syndrome versus being a complication of other illnesses has gained renewed interest. The prevalence of catatonia in consultation-liaison services is approximately 5.5 percent in patients over 65 years of age.³

Catatonia is a heterogeneous disorder with at least 40 documented signs and symptoms making it difficult to diagnose and classify.⁴ The disorder has been characterized into three subtypes⁵:

- **Stuporous catatonia**, the most common subtype, may be distinguished by mutism, posturing, negativism, and staring.
- **Excited catatonia** may be distinguished by hyperkinesia, restlessness, combativeness, impulsivity, and stereotyping.
- **Malignant catatonia** is life-threatening and characterized by fever, delirium, autonomic instability, and rigidity.

The pathophysiology of catatonia is not well understood; genetic factors are thought to play a part.¹ There are several theorized pathways:

- Dysfunction of the GABAergic pathways⁶
- Hyperactivation of the orbitofrontal cortex (OFC) and ventromedial prefrontal cortex (VMPFC)²
- An outward expression of overwhelming anxiety.¹ The connection between the basal ganglia and the cortex may be involved.

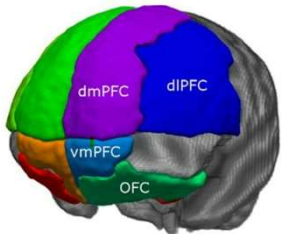


Figure 1. Illustration of VMPFC, OFC, and other brain regions.⁷

fMRI studies have shown connection between hyperactivation of the OFC and VMPFC in patients with acute catatonia. Decreases in hyperactivation were observed with lorazepam administration in successfully treated patients.²

Case presentation

A 66-year-old AA male with chronic schizophrenia and recurrent catatonia was admitted to a medical unit with diagnosis of failure to thrive. He was transferred from a state psychiatric hospital after not eating for 3 days and exhibiting mutism and immobility. He had not taken his medications for about 2 weeks. His prescribed medications included chlorpromazine, quetiapine, oxcarbazepine, and clonazepam. Upon psychiatric consult, patient was found to have symptoms of staring, grimacing, echopraxia, and negativism. He was diagnosed with stuporous catatonia and lorazepam challenge was initiated. 30 minutes after administration of 2 mg of intravenous lorazepam, the patient was able to move, converse, and eat. After a second dose of lorazepam 2 mg IV, the patient became excited and difficult to redirect, displaying stereotypic movement, verberation, yelling, and hitting. Additional doses of lorazepam were unsuccessful in breaking the excited catatonia. This was the second such instance of this patient transitioning from stuporous to excited catatonia after administration of multiple doses of lorazepam.

Past history reveals previous catatonic episodes, most recently 9 months prior to the current presentation when the patient was admitted to a gero-psychiatric unit. He initially presented in stuporous state. During that hospitalization, the patient received up to 16 milligrams of lorazepam daily without successful termination of excited catatonia. Zolpidem challenge was unsuccessful. Switch to carbamazepine led to agitation and was discontinued. Clozapine and valproic acid were trialed with minimal improvement. Catatonia was successfully treated with 10 sessions of electroconvulsive therapy (ECT) in combination with clozapine and valproic acid. Maintenance ECT was not continued because of the COVID pandemic, and the patient was ultimately admitted to state facility on a combination of lorazepam, clozapine, and amantadine.

Treatment

Lorazepam is the first-line treatment and diagnostic challenge, implicating the GABAergic pathways. Other benzodiazepines are also effective.⁶

ECT is the definitive treatment for catatonia and has been reported to elicit a response in 80 to 100 percent of cases⁸

NMDA antagonists (amantadine and memantine), antiepileptics (carbamazepine, valproic acid, topiramate), and select second generation antipsychotics (aripiprazole, olanzapine, clozapine) are other viable treatment options⁸

Discussion

Catatonia is commonly encountered on consultation-liaison services in the general hospital setting. This patient demonstrated an unusual and unexpected presentation - conversion of stuporous catatonia to excited catatonia after administration of multiple doses of lorazepam. The administration of a benzodiazepine will typically result in improvement of the patient's symptoms or will fail to elicit any response.

A thorough literature search was performed and no other cases involving the repeated conversion of stuporous to excited catatonia were found. We hope this patient's clinical course may provide insight for the treatment of patients with treatment-resistant catatonia and those with paradoxical response to benzodiazepines in the context of catatonia. Recognition of this conversion may be difficult and may require development of a catatonia scale that results in clear identification of the presenting subtype from the other subtypes.⁹ As signs are not mutually exclusive between the subtypes, this is a challenge.

Conclusion

The atypical presentation of stuporous catatonia converting to excited catatonia with the administration of lorazepam on two documented occasions highlights the importance of recognizing the possible switch between catatonia subtypes and the continuation or escalation of treatment. Development of a diagnostic rating scale that clearly identifies the presenting catatonia subtype may improve recognition of this phenomenon in difficult clinical situations.

References

1. Rasmussen SA, Mazurek MF, Rosebush PI. Catatonia: Our current understanding of its diagnosis, treatment and pathophysiology. *World Journal of Psychiatry*. 2016;6(4):391.
2. Kaelin J, Abujam A, Edriweera H, Macfarlane MD. Prevalence and symptomatology of catatonia in elderly patients referred to a consultation-liaison psychiatry service. *Australasian Psychiatry*. 2015;24(2):164-7.
3. Solmi M, Pigato GG, Roiter B, Guaglianone A, Martini L, Fornaro M, et al. Prevalence of catatonia and its moderators in clinical samples: Results from a meta-analysis and meta-regression analysis. *Schizophrenia Bulletin*. 2017;44(5):1133-50.
4. Fink M, Taylor MA. The catatonia syndrome. *Archives of General Psychiatry*. 2009;66(11):1173.
5. Lloyd JR, Silverman ER, Kugler JL, Cooper JJ. Electroconvulsive therapy for patients with catatonia: Current perspectives. *Neuropsychiatric Disease and Treatment*. 2020;Volume 16:2191-208.
6. Eklul P, Choucha W. Neurobiological approach of Catatonia and Treatment Perspectives. *Frontiers in Psychiatry*. 2015;6.
7. Eden AS, Schreiber J, Anwender A, Keuper K, Laeger I, Zwanzger P, et al. Emotion regulation and trait anxiety are predicted by the microstructure of fibers between amygdala and prefrontal cortex. *The Journal of Neuroscience*. 2015;35(15):6020-7.
8. Beach S. Treatment Strategies for Catatonia [Internet]. *Psychopharmacology Institute*. 2020 [cited 2021Aug]. Available from: <https://psychopharmacologyinstitute.com/section/catatonia-treatment-strategies-take-home-messages-2500-4710>
9. Stenaert P, Rooseleer J, De Fruyt J. Measuring catatonia: A systematic review of Rating Scales. *Journal of Affective Disorders*. 2011;135(1-3):1-9.