



Hip Abduction Contracture Treated With Botulinum Toxin in a Non-Spastic Patient With Spinal Cord Injury: A Case Report

Andrew Lai, DO; Shane Davis, MD; Bi-Ying Yeh, MD - UCI Dept. of Physical Medicine and Rehabilitation

Case Diagnosis

- A 35-year-old male with T12 ASIA C spinal cord injury presented with a hip abduction contracture.

Case Description

- This patient presented with low back pain while sleeping at night. While lying supine, with hips and knees extended, his legs would abduct and externally rotate. Physical therapy with daily stretching yielded no improvement.
- On examination his knees easily came together while seated in his wheelchair. Passive hip adduction was difficult, but only while supine. There was no spasticity in the lower extremities.
- Due to the patient's hip abduction contracture when supine, it was presumed that he had iliotibial band tightness.
- To decrease hip abduction and external rotation, the tensor fasciae latae and sartorius were targeted with botulinum toxin. Each muscle was injected with 50 units of onabotulinumtoxinA bilaterally using landmarks, as there was no electrical activity to allow for EMG targeting.
- Subsequently, the continuation of twice-weekly physical therapy yielded improvement in passive hip adduction (10-20°), hip extension (4-8°) and knee extension (5°), as well as pain.

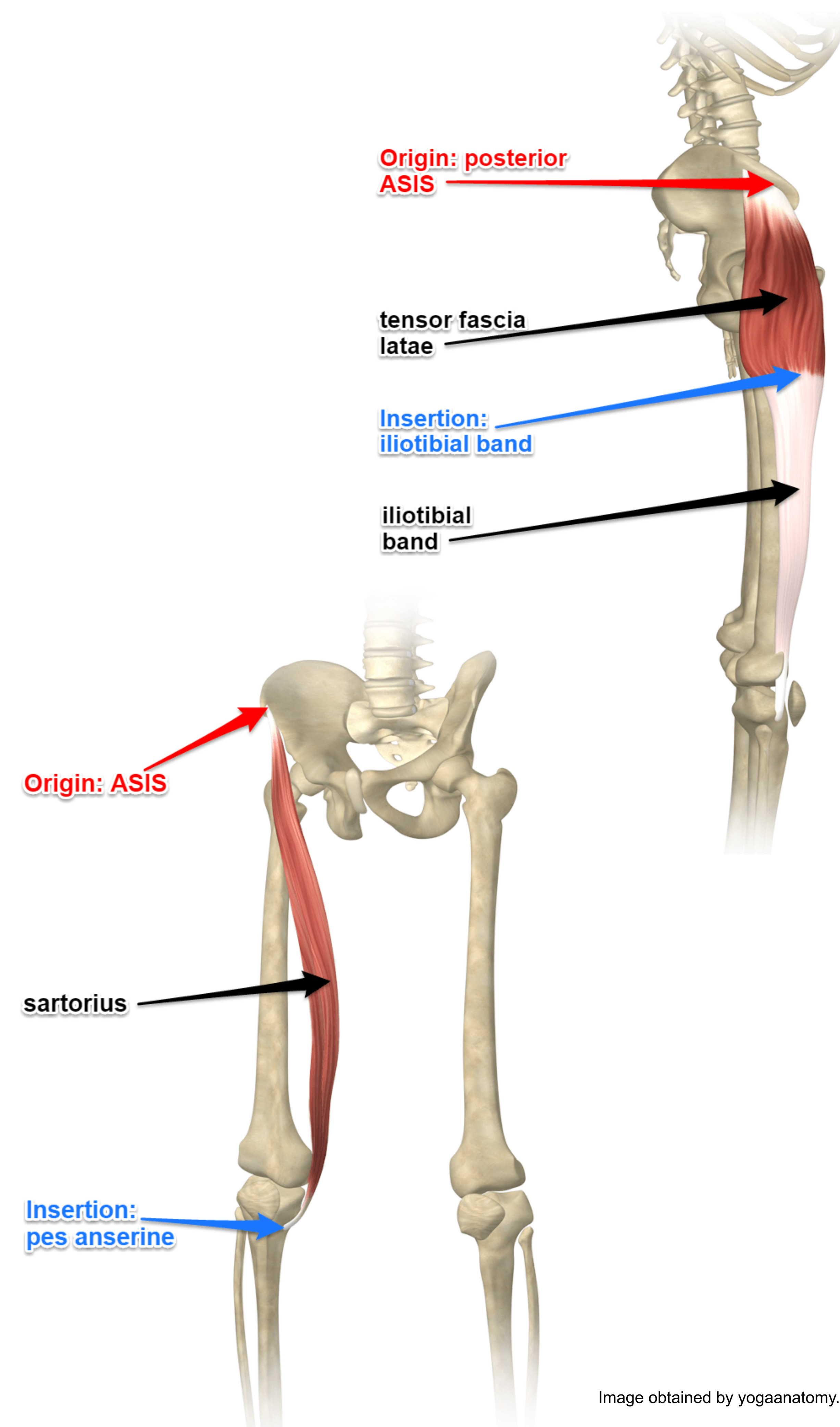


Image obtained by yogaanatomy.com

Discussion

- Contractures, defined as shortening of muscle or connective tissue, can be caused by prolonged spasticity or immobility and are commonly seen in the spinal cord injury population.
- Traditional treatments include stretching and splinting, with refractory cases often requiring surgical release.
- Botulinum toxin injection is a proven treatment option for spasticity-related contractures, although its role in treating contractures without spasticity is not well-established.
- This case demonstrates its use as an effective adjunct to therapeutic stretching in a spinal cord injury patient with hip abduction contracture in the absence of spasticity.

Conclusion

- For patients with spinal cord injuries who develop painful hip abduction and external rotation contractures, botulinum toxin injection of the tensor fasciae latae and sartorius can result in improved range of motion and decreased pain.