



# Neuropathic pruritus after basal ganglia hemorrhage.

Kristen Huang, B.S., Vivian Chiu, B.S., Allison J. Zhong, B.S., Samantha Sabban-Wang, D.O., Md Alal Uddin, M.D., Mohammad Islam, M.D.

NYC  
HEALTH+  
HOSPITALS

Metropolitan

## BACKGROUND

An itch (pruritis) is a common phenomenon that usually results in a scratch response, providing only temporary relief. The sensation has been thought of as the skin's protective mechanism against foreign agents, with the response originating in the skin and its transitional tissues, but it can also arise from neurological lesions, such as following a stroke or with a peripheral neuropathy. Neuropathic pruritus is a pathological phenomenon in which normal sensation becomes altered, and an itch sensation begins to occur that is independent of pruritogenic stimuli. Although pruritus is usually not as severe of a symptom as pain, it can be difficult to treat and if severe, can lead to persistent changes in quality of life for a patient. In this report, we will discuss a case in which a patient experienced post-stroke pruritis in the distribution of his hemiparesis.

## CASE PRESENTATION

A 71-year-old male with no past medical history presents to acute inpatient rehabilitation facility after a left basal ganglia hemorrhage secondary to uncontrolled hypertension. He presented with right sided hemiparesis, pronator drift, gait instability and right-sided decreased sensation. Nine days after the inciting event, the patient developed pruritus on the right side of his body including the right extremities, abdomen, and face. The following day, the patient reported improvement in symptoms with pruritus localized only to the right lower extremity, below the knee. The patient was started on amitriptyline for his pruritus, with resolution of symptoms after two days.

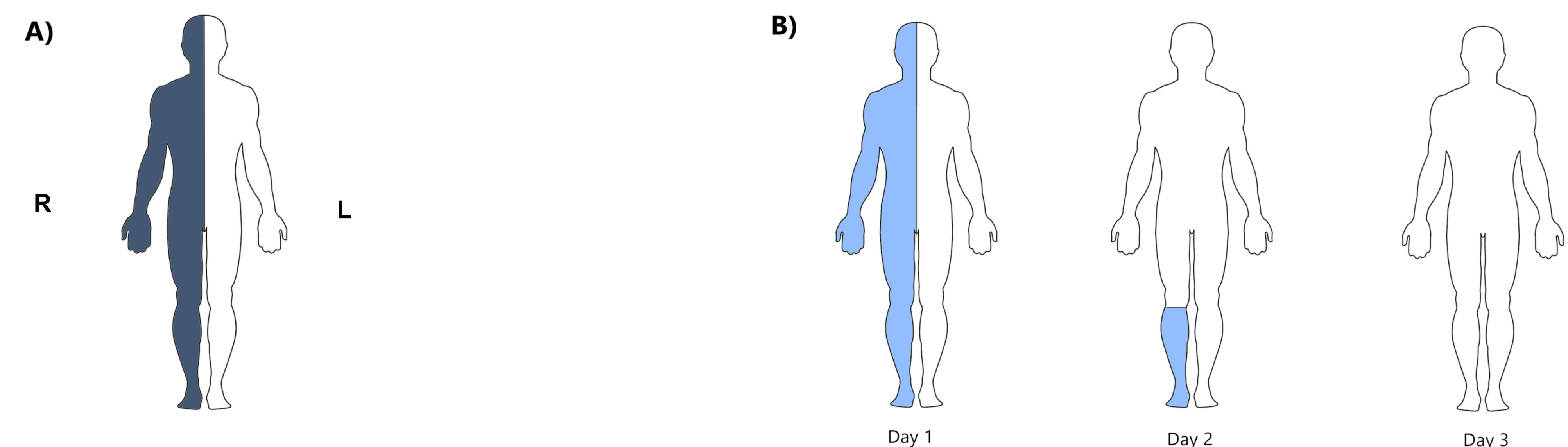


Figure 1. A) Location of patient's general symptoms post-hemorrhage. B) Location and timecourse of patient's pruritus.

## DISCUSSION

Neuropathic pruritus has been associated with many types of neurological pathologies resulting in pain or sensory loss, such as multiple sclerosis, stroke, radiculopathy, and shingles, with central causes occurring less often. Although the mechanisms are still unknown, theories of injury to neuropathic pathways, sensory signals, and central disinhibition have been implicated. The sensation of itch, along with pain, is carried by small unmyelinated (C-fibers) and thinly myelinated axons (A-delta fibers), and are usually involved in response to injury. Even if direct injury is not involved, theories suggest that injury and inflammation to other axonal types can cause a "bystander" effect and damage other nearby axons, including those transmitting the sensation of itch. The most common complication of neuropathic itch is self-injury, often from scratching and injuring deeper tissue layers. This often occurs in conjunction with sensory loss of the affected side, which is commonly seen in cerebrovascular accidents (CVAs). Some cases in the literature have described neuropathic pruritus in the trigeminal distribution, but few cases have described more widespread neuropathic pruritus following CVAs.

## CONCLUSIONS

Following a CVA, patients can experience neuropathic pruritus in addition to hemiparesthesia to the contralateral side. Neuropathic pruritus has a good prognosis and often resolves within weeks, either with topical emollients or with medications, such as amitriptyline.

## BIBLIOGRAPHY

- Dhand, Amar, and Michael J. Aminoff. "Neurology of Itch." *OUP Academic*, Oxford University Press, 21 June 2013, [academic.oup.com/brain/article/137/2/313/281238](http://academic.oup.com/brain/article/137/2/313/281238).
- Kimyai-Asadi, Arash, et al. "Poststroke Pruritus." *Stroke*, vol. 30, no. 3, 1999, pp. 692–693., doi:10.1161/01.str.30.3.692.
- Massey, E W. "Unilateral Neurogenic Pruritus Following Stroke." *Stroke*, vol. 15, no. 5, 1984, pp. 901–903., doi:10.1161/01.str.15.5.901.
- Oaklander AL. Neuropathic itch. *Semin Cutan Med Surg*. 2011;30(2):87-92. doi:10.1016/j.sder.2011.04.006