

Platelet-Rich Plasma (PRP) and Fenestration for Treatment of Distal Patellar Tendinopathy: A Case Report

Haruki Ishii, MD, Rosa M. Pasculli, MD, MBA, Brendan Skeehan, DO, Dallas Kingsbury, MD

RUSK REHABILITATION, NYU LANGONE HEALTH, NEW YORK, NEW YORK 10016

Case History

INITIAL PRESENTATION

- A 52-year-old male presented with a five-month-history of atraumatic left anterior knee pain
- The pain is dull and aching during exercise, including running, cycling, and surfing
- Denies weakness, numbness, or paresthesia
- Physical exam was notable for the tenderness of the patellar tendon at the proximal and distal tibial tuberosities
- Left knee X-rays: unremarkable
- The patient was referred to PT

AT FOLLOW UP VISIT

- At follow-up, patient reported minimal improvement despite physical therapy
- Ultrasound of the left knee demonstrated distal, but not proximal, hyperechoic thickening of the patellar tendon with hyperemia and enthesopathy without high grade tear, consistent with **distal patellar tendinopathy**
- The patient then underwent PRP injection with fenestration

Tests and Results

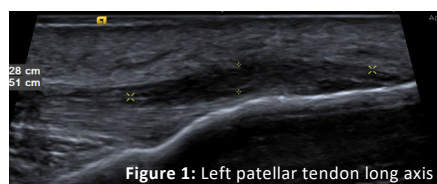


Figure 1: Left patellar tendon long axis

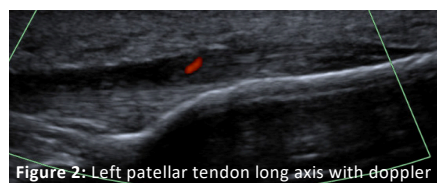

Figure 2: Left patellar tendon long axis with doppler

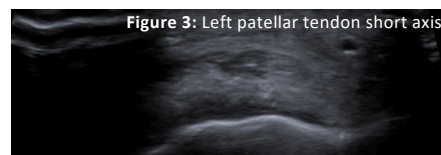


Figure 3: Left patellar tendon short axis

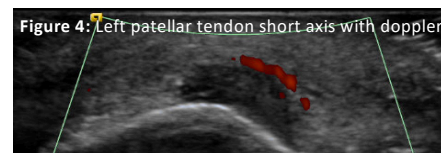

Figure 4: Left patellar tendon short axis with doppler

Outcome

After PRP injection with fenestration

- Resulted in 75% pain reduction at one-month post injection with only minimal localized tenderness to palpation
- Patient returned to his exercise routine without recurring pain

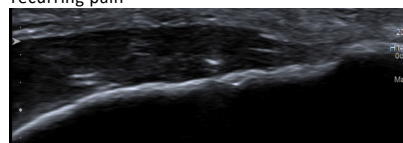


Figure 5: Patellar tendon fenestration long axis

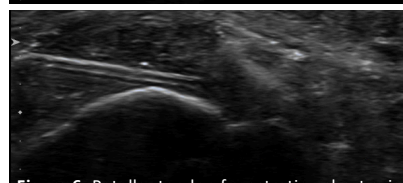


Figure 6: Patellar tendon fenestration short axis

Discussion

- Patellar tendinopathy is a chronic degenerative process, often leading to anterior knee activity-related pain in recreational and elite athletes
- Most commonly seen in the inferior pole of the patella at the proximal insertion of the patellar tendon
- Patellar tendinopathy typically presents with pain more prominent in the patellar tendon
- In approximately 10% of cases, the distal insertion of the patellar tendon can be affected, although only few cases have been reported in the literature
- Reducing painful, high tendon load and gradually introducing beneficial tendon load via eccentric exercises are the main initial approach
- Additional intervention is often required including platelet-rich plasma (PRP) injection, shown to be effective for refractory patellar tendinopathy

Tendinopathy vs. Apophysitis

- Osgood-Schlatter Disease (tibial tuberosity apophysitis) is an example of apophysitis which results from a traction injury to the cartilage and bony attachment of tendons in **children**
- Patients with distal patellar tendinopathy have pain in closer to tibial tuberosity, similar to Osgood-Schlatter disease complains of the pain. And thus, it is important to know what differentiates the two pathologies

Conclusion

- This case highlights the effectiveness of PRP injection for refractory distal patellar tendinopathy

References

- Achar, S., & Yamanaka, J. (2019). Apophysitis and osteochondrosis: Common causes of pain in growing bones. *American family physician*, 99(10), 610-618.
- Andriolo, L., Altamura, S. A., Reale, D., Candrian, C., Zaffagnini, S., & Filardo, G. (2019). Nonsurgical treatments of patellar tendinopathy: multiple injections of platelet-rich plasma are a suitable option: a systematic review and meta-analysis. *The American journal of sports medicine*, 47(4), 1001-1018.
- Dupley, L., & Charalambous, C. P. (2017). Platelet-rich plasma injections as a treatment for refractory patellar tendinosis: a meta-analysis of randomised trials. *Knee surgery & related research*, 29(3), 165.
- Everhart, J. S., Cole, D., Sojka, J. H., Higgins, J. D., Magnussen, R. A., Schmitt, L. C., & Flanigan, D. C. (2017). Treatment options for patellar tendinopathy: a systematic review. *Arthroscopy: The Journal of Arthroscopic & Related Surgery*, 33(4), 861-872.
- Ferretti, A. (1986). Epidemiology of jumper's knee. *Sports medicine*, 3(4), 289-295.
- Liddle, A. D., & Rodríguez-Merchán, E. C. (2015). Platelet-rich plasma in the treatment of patellar tendinopathy: a systematic review. *The American journal of sports medicine*, 43(10), 2583-2590.
- Sarimo, J., Sarin, J., Orava, S., Heikkilä, J., Rantanen, J., Paavola, M., & Raatikainen, T. (2007). Distal patellar tendinosis: an unusual form of jumper's knee. *Knee surgery, sports traumatology, arthroscopy*, 15(1), 54-57.